v 61 T
11253
no. 19

TREASURY DEPARTMENT
Public Health and Marine-Hospital Service of the United States

TRACHOMA

ITS CHARACTER AND EFFECTS

BY

PASSED ASST. SURG. T. CLARK

AND

PASSED ASST. SURG. J. W. SCHERESCHEWSKY

PREPARED BY DIRECTION OF THE SURGEON-GENERAL

WASHINGTON
GOVERNMENT PRINTING OFFICE
1907

Digitized by the Internet Archive
in 2007

http://www.archive.org/details/trachomaeffects00unit

Property of the United States Government

TREASURY DEPARTMENT
Public Health and Marine-Hospital Service of the United States

TRACHOMA

ITS CHARACTER AND EFFECTS

BY

PASSED ASST. SURG. T. CLARK

AND

PASSED ASST. SURG. J. W. SCHERESCHEWSKY

PREPARED BY DIRECTION OF THE SURGEON-GENERAL

WASHINGTON
GOVERNMENT PRINTING OFFICE
1907

617

INTRODUCTORY NOTE.

The increasing prevalence of trachoma in the United States attracted widespread attention for some years prior to 1897. Cases and outbreaks of the disease, especially among school children and the alien population, were noted by numerous observers, and because of the contagiousness of the disease and the seriousness of its sequelæ, it was regarded as a menace to the public health.

Fewer cases had been observed among native-born Americans, and the increase was attributed to the influx of a large alien population to the congested centers along the Atlantic seaboard and elsewhere.

During the past twenty-five years immigrants have come from as many countries. During the first fifteen years of this quarter of a century the bulk of immigration came from northern Europe, principally Germany, Scandinavia, and the British Isles—countries in which trachoma is relatively infrequent. During the past twelve years the tide of immigration from southern Europe has been steadily increasing, until at the present time the larger part of the alien population arriving at our shores originates in Italy, Austria-Hungary, the Russian Empire, and countries bordering on the northern and eastern shores of the Mediterranean.

This change in the source of arriving immigrants and resulting difference in the character of the people is very significant and in all probability accounts for the marked increase of the disease noted above.

Prior to 1897 ophthalmologists and representative bodies urged that immediate steps be taken to prevent the further importation of the disease, in the belief that such precautions would be an important factor in the elimination of the disease from the country. Dr. Miles Standish, of Boston, an eminent authority on diseases of the eyes, in an article which appeared in the Medical Communications of the Massachusetts Medical Society, vol. 17, No. 11, referred to this question in part as follows:

> I may say in passing that the presence of acute trachoma in the conjunctiva of immigrants should be a good and sufficient reason for turning them back whence they came. A large proportion of these cases within a few months after their arrival become incapacitated and are public charges. And not only

this, but were it not for the new cases thus introduced in the great tenement localities of our large cities, it is my opinion that the disease would soon become extremely rare in this part of the country.

No doubt existed as to the seriousness of trachoma. Its contagious character was admitted, and it was believed that fresh importations only served to propagate the disease and cause additional burdens on the State. A communication was therefore addressed to the Commissioner of Immigration October 30, 1907, declaring that the disease should be classified as "dangerous contagious," in accordance with the immigration law of 1891, thus making mandatory the deportation of all arriving aliens who are so afflicted.

Since that time thousands of aliens afflicted with trachoma have been certified at United States ports and excluded from landing.

Great care is required in making these examinations, as the landing of aliens so afflicted would insure the propagation of the disease. On the other hand, the certification of cases not so afflicted would result in untold hardship to the immigrant. A correct differential diagnosis of inflammatory diseases of the conjunctiva is therefore of the greatest moment, and it is important that public health officials engaged in such work should have a clear conception of the character and effects of trachoma.

TRACHOMA.

By Passed Asst. Surg. Taliaferro Clark.

Trachoma is derived from the Greek word τραχύς, meaning rough, hence the origin of the expression "granular lids."

In 1897 this disease was classed under the head of "dangerous contagious" disease by the United States Public Health and Marine-Hospital Service, thus making mandatory the deportation of aliens so afflicted, under section 2 of the immigration laws.

Trachoma is not a dangerous contagious disease in the sense that it is dangerous to life, but by reason of its destructive effect on the tissues of the eye, with resulting blindness. The disease is characterized briefly in its early stages by swelling of the conjunctiva, accompanied by the formation of hyperplastic papillæ, profuse secretion, followed by a more or less prolonged period of cicatrization.

ETIOLOGY.

Possibly in connection with no other disease of the eye is medical literature so voluminous. In spite of the patient investigation of many, the actual causative factor has not yet been discovered; hence the many widely divergent views regarding this disease, dependent upon the personal equation of the observer and his opportunity for the study of this affection.

The disease is due to infection. Its secretions are infective, and its continuance is due to the direct transfer of infectious material from the diseased eye to those otherwise normal. It is to be hoped that with improved microscopic technique and a better understanding of stains and methods of staining the cause of trachoma shall soon be discovered. The presence of the known infective agent being determined would settle for all time the contagiousness of this disease in certain of its stages, about which there is a considerable difference in opinion.

It is a well-known fact that the pathogenic micro-organisms which are known to excite inflammation of the conjunctiva may be divided into two classes, namely, conditionally and unconditionally infectious.

It is possible that the infective agent of trachoma belongs to the first class. This is evidenced by the fact that we see trachoma in one eye and the other eye normal in the same individual. We see members of the same family, some badly infected and others without traces of the disease. These facts warrant the assumption that in addition to the presence of the infective agent there must be a certain nonresistive condition of the tissue present before the infective agent can produce a trachomatous inflammation of the conjunctiva. It is due to this fact that such a large percentage of the cases of this disease is found among people ignorant of the laws of hygiene, who are poorly developed and nourished, and who live in the midst of insanitary surroundings, whose vitality is low. Still, it must be borne in mind that these conditions are most favorable for the transfer of the contagious element from one person to another.

PATHOLOGY.

Microscopic examination of a section of the conjunctiva in the early stages of trachoma reveals the presence of numerous aggregations of lymph cells which shove up the conjuntiva, forming the small elevations that give to this disease its characteristic aspect. These undergo organization with the formation of connective tissue, which, continuing and subsequently contracting, produce the characteristic changes in the eye subsequently to be described. The amount of this infiltration is dependent upon several factors—low resistive power in the tissue of the eye itself, the virulence of the exciting agent, the swiftness and the intensity of the inflammation, resulting in greater or less degree of destructive changes in the eyelid, and in the eye itself.

SYMPTOMS.

Trachoma has been found in the lower lid in but a small percentage of the cases which have come under my personal observation.

The onset of an acute attack of trachoma is the same as that of any other acute inflammatory condition of the conjunctiva; there is photophobia, lachrimation, presence of secretion, redness, swelling of the conjunctiva. If the lid be everted it will be found that the surface of the palpebal conjunctiva is swollen, red, moist, and thrown into folds. Here the analogy ceases. Later, after a period of a week or more, this surface will be found studded with elevations that present a glistening, berry-like aspect. These elevations vary in color, proportionate to the intensity of the inflammation; in size, to the density of normal tissues of the tarsus. The connective tissue of the tarsus being denser than that in the fornix conjunctivæ, it is patent that the elevations of the tarsal conjunctiva will be smaller than

those in the fornix, where the tissue is more lax. After a more or less prolonged period the photophobia and lachrimation disappear, symptons of acute inflammation subside, secretion diminishes in amount, and the formation of cicatricial tissue is observed. This last change leaves an indelible impress on the conjunctiva, so that the skilled observer may read its story like the pages of an open book. It is this fact, the formation of scar tissue, that distinguishes trachoma from all other acute inflammatory conditions of the conjunctiva not dependent upon traumatism. In these latter cases the history of traumatism is always obtainable, such as the burning from lime. In all inflammations of the conjunctiva excited by known pathogenic bacteria, when the symptoms subside the conjunctiva returns to its normal condition unchanged. They leave no traces behind them.

Not all cases of trachoma begin so acutely. In many instances the disease begins so insidiously that the afflicted person is unaware that he has anything serious the matter with his eye until his attention is called to the fact. This is especially true of those cases arising and are seemingly confined to the retrotarsal fold. It is in this situation that granulations are larger, lighter in color, more irregular in outline, sometimes arranged in rows, translucent, sometimes in irregular gelatinous masses, which have been likened to frog spawn. The conjunctiva is thickened and the subconjunctival blood vessels are obliterated. The conjunctiva presents a meaty-like aspect. These cases, seemingly so benign, can light up, as it were, and assume the gravest proportions.

COMPLICATIONS.

Pannus is of frequent but not invariable occurrence in trachoma. It usually forms on the upper segment of the cornea. A hazy mass is observed to spread out over the cornea, even sometimes covering its whole surface, beneath which may be seen fine blood vessels in reticular arrangement.

Pannus is seen in the most virulent types of trachoma, those characterized by swiftness in destructive changes. The formation of pannus is sometimes accompanied by such softening of the corneal structure as to produce ectasia corneæ. The most frequent seat of ulcer of the cornea in trachoma is usually at the free margin of the pannus, and it is produced by the same softening of the corneal structure. The pannus, with the subsidence of other symptoms, may be reabsorbed, clear up, leave no change; at other times may persist in the form of corneal opacity that may result in the loss of vision.

COURSE AND DURATION.

Unless treatment be instituted in the very early stages of the disease, it may be said that trachoma is never cured. Cases apparently cured, on which treatment is stopped too soon, undergo acute exacerbations and become as active and as virulent as ever. Indeed, these exacerbations are observed in many cases while undergoing active treatment.

The stage of connective tissue formation and contraction continues until there is complete destruction of the subconjunctival lymphoid tissue. This change may take years to produce.

Until such change has taken place there is always a possibility that the disease may become active.

A trachomatous eye in its quiescent stage is subject to acute inflammation from other agents productive of conjunctivitis, the same as any other eye. It must be borne in mind that there is always a possibility that the infective agent of trachoma may be latent, as is so often observed in cases of gonorrhea, its process may be temporarily arrested as in tuberculosis, but with the onset of acute inflammation from other causes its secretions may be capable of conveying trachomatous infection. It is therefore necessary to classify trachoma as a dangerous contagious disease until the completion of the stage of scar tissue formation.

In the last and latest stages of trachoma we see the effects of cicatricial contraction—entropion, ectropion, trichiasis, districhiasis, xerosis, symblepharon, corneal opacities that have resulted from healed ulcers, and pannus. The mucous membrane is pearly and glistening, frequently passing directly from the lids to the bulb, obliterating the retrotarsal fold.

DIAGNOSIS

For the purpose of diagnosis, trachoma may be divided into three stages, viz:

1. Acute.
2. Connective-tissue stage.
3. Stage of contraction.

The early diagnosis of trachoma is of the greatest importance, not only to the individual, but to the community as well.

Several well-recognized micro-organisms have been isolated as the cause of acute conjunctivitis, namely: Koch's Weeks bacillus, the diplococcus of Axenfeld and Morax, the pneumococcus of Fränkel and Weichselbaum, etc.

ACUTE STAGE.

As a preliminary step in the diagnosis of acute trachoma a microscopic examination should invariably be made to determine the presence of one or the other mentioned exciting causes. The possibility of a mixed infection, as exemplified in other well-known inflammatory conditions, must always be borne in mind, yet the presence or absence of one or the other of the exciting agents above enumerated is of great assistance in enabling us in arriving at a conclusion when time is a consideration. Especially is this true because of the fact that the pathogenic organism of trachoma yet remains to be discovered, and until such is the case a diagnosis of this affliction in its acutest stage will present many difficulties to those who have had but a limited opportunity to study this disease, and more especially in those cases that depart widely from the classical description.

The observer should regard with strong suspicion all cases of acute conjunctivitis existing in persons coming from countries where this disease is known to be endemic, or from localities where foci of infection are known to exist.

In acute conjunctivitis is observed the same swollen, velvety condition of the conjunctiva as in the early stage of trachoma, also there is photophobia, lachrimation, increased secretion, and hypertrophied follicles, which may readily be mistaken for the true papillary hyperplasia of trachoma. Such cases should be held under observation for one or two weeks and proper remedial measures instituted. If, in spite of such treatment, the inflamation continues acute, the granulations persist, we may, with great certainty, declare the affection to be that of acute trachoma.

In all cases of acute conjunctivitis, dependent upon known infective agents, when acute symptoms subside, it will be found that the conjunctiva has undergone no change; on the other hand, in trachoma, it is found that treatment has only modified the inflammation, arrested for the time being its progress, and changed somewhat the typical aspect of the disease.

This brings us to the consideration of the second stage, or stage of connective tissue formation. In this stage (pl. 2) there are no outward signs of inflammation. The trained observer will note a thickening of the lids; the palpebro-tarsal fold is but slightly marked; the movement of the lids are sluggish, do not follow the eyeballs on looking down—lag behind. In some instances the lids present a drooping appearance, obscure the upper half of the pupil, present the so-called "semiluna" aspect. Coincident with this drooping of the lids, the skin of the forehead is wrinkled, as is often observed in ptosis, congenital, or due to affections of the motor oculi nerve.

It must be remembered not all of these conditions may be present

in any one case, indeed all may be absent. Therefore it is necessary to evert the upper eyelids of all persons presenting themselves for examination. In this stage, depending upon the progress of the disease, the conjunctiva will be found studded with the "granulations" of trachoma. These so-called granulations are not granulations in the sense as used in the connection with an open wound, but are covered with epithelium. These elevations vary in color from almost white to a deep red—determined by the amount of inflammation present. They vary in size in different individuals and as to locations; being smaller on the tarsal conjunctiva, where the normal tissues are dense, and larger in the more lax tissue of Krause's fold. Early in this stage of the disease (fig. 2) minute striation of newly-formed connective tissue will be found radiating throughout this mass of granulation. This is an invariable and distinctive sign of trachoma. In no other inflammation of the conjunctiva is it found.

In the more advanced cases (Fig. IV) these striations have widened; the hyperplastic papillæ smoothed down. The small subconjunctival vessels, normally observed passing forward over the lid from the retrotarsal fold, are obliterated.

ANOTHER DISTINCTIVE FEATURE.

The obliteration of blood vessels in this stage must not be confounded with the obliteration of vessels due to the swelling from acute inflammatory conditions of the earliest stages of conjunctivitis. The former is due to the contraction and is more or less permanent; the latter to swelling and is transitory. This process of scar tissue formation continues, leaving here and there little islands of granulation, until finally there is entire destruction of the subconjunctival lymphoid tissue, leaving the conjunctiva smooth, pale, pearly, fibrous. Pari passu with the changes just enumerated, contraction with distortion of the lids is taking place, marking the last or contracting stage of trachoma (Fig. VI).

In this stage is found entropion or ectropion; trichiasis or districhiasis; the conjunctiva pale, smooth, and scarred; the remains of corneal ulcers and unabsorbed pannus; possibly blindness; in fine, the effects of a severe inflammatory condition.

DIFFERENTIAL DIAGNOSIS.

Trachoma must be differentiated in its first stage from acute conjunctivitis and in its second stage from—

(a) Follicular conjunctivitis,

(b) Adenomatous conjunctivitis, and

(c) Vernal catarrh (Früjahr's conjunctivitis).

In acute conjunctivitis the diagnosis is made by time, observation, and treatment, in connection with microscopic examination.

FOLLICULAR CONJUNCTIVITIS.

Follicular conjunctivitis can only be confounded with the so-called benign types of trachoma, especially those cases in which the disease is largely limited to the retrotarsal fold. In follicular conjunctivitis there is follicular hypertrophy, never a true papillary hyperplasia. There is never formation of cicatricial tissue. The minute subconjunctival vessels passing forward on the under surface of the lid are never destroyed. At times in follicular conjunctivitis these hypertrophied follicles are observed to have undergone calcareous or fatty degeneration. This is characteristic of hypertrophy, never of hyperplasia, and should never be confounded with a trachomatous inflammation. Follicular conjunctivitis can be cured and leaves the conjunctiva unchanged.

ADENOMATOUS CONJUNCTIVITIS.

For the want of a better term this expression is used to define an adenomatous condition sometimes observed of Krause's follicles, situated in the retrotarsal fold. In this situation are found irregular gelatinous masses that might be mistaken for trachoma bodies. If the lids are rolled with Knapp's forceps, followed by astringent applications, this condition disappears without reaction; in trachoma the reverse is the case.

VERNAL CATARRH, OR FRÜJARS CONJUNCTIVITIS.

This is a chronic disease. On the under surface of the lid will be found parchment-like elevations, larger than the trachomatous granulations, in a mosaic-like arrangement. These papillæ are broad and flattened, and over the whole a milky film is observed. While this condition is chronic, on recovery it leaves no changes in the conjunctiva.

TYPES OF TRACHOMA.

Many observers have divided trachoma into various types, resulting only in confusion in diagnosis. There is no such thing as kinds of trachoma; it is always one and the same disease, varying in aspect only as modified by the severity of the infection, the intensity of the inflammatory process, the natural resistance of the tissues, and the varying density of the subconjunctival tissue in individuals and in situation. The papillæ are larger in the fornix, where the tissues are lax, and smaller on the tarsus, where the tissues are denser. As these two types of papillary formation shade one into the other, modified by the varying amount of inflammation present, writers have endeavored to classify this disease into confusing subdivisions.

PROGNOSIS.

But few cases of well-defined trachoma are ever cured. The disease may be arrested and its course modified and its ravages restricted by treatment. Many cases discharged as cured, or in which treatment is stopped too soon, undergo acute exacerbation. Treatment can only modify; time eliminates the disease as a dangerous contagious condition. The period of communicability is followed by a prolonged stage in which destructive changes take place, due to pressure, irritation, lack of protection, and nonlubrication by the normal secretion, and which may result in blindness.

EFFECT OF THE DISEASE ON INDIVIDUALS.

About 75 per cent of untreated cases of trachoma result in blindness, and it is for this reason considered a dangerous contagious disease, and not because of any danger to the life of the individual. When the disease arises in a young child he is debarred by municipal regulations from the public schools at an age when the mind is the most receptive, when the soil is in cultivation for the future harvest of intellectual usefulness. When it occurs in early manhood the door of professional study is practically closed. When defective vision or blindness result he is prevented from laying up in the storehouse of his mind those mental pictures derived from the study of art, literature, and science, among which his imagination could run riot to the solace of his declining years. Indeed his lot is most pitiful.

An eminent opthalmologist has stated that he would prefer his child would have smallpox rather than trachoma. In the one case he either dies or recovers, in the other his life is inevitably made miserable.

EFFECTS ON THE COMMUNITY.

The unrestricted importation of trachoma is fraught with grave dangers, owing to the establishment of foci of infection. The disease is largely recruited from those who are ignorant of and who do not practice sanitary measures. When introduced into a community the focus of infection is usually found in a congested district, inhabited by the very poor, from which class the maids, cooks, laundresses, and other servants are recruited to the no small danger of the families of the employers. In the schools an undetected case of trachoma may infect an innocent little desk mate. In orphan asylums and other eleemosynary institutions the history of this terrible disease shows that an epidemic once started is most difficult to control.

In communities where trachoma is endemic it has been reported that 60 per cent of the cases of blindness are due to this terrible malady.

In the United States, where the disease has been imported, about 4 per cent of the cases of contagious conjunctivitis were due to this disease, prior to the adoption of more stringent inspection methods. The cost of the maintenance of persons who have become blind by reason of trachoma, is a no small incentive to a community to protect itself.

THE EFFECT OF RESTRICTIVE LEGISLATION.

(A) Against the establishment of new foci. In communities where trachoma is not endemic, foci of infection can only be established through the importation of this disease. Its prevention can only be accomplished by rigid inspection of arriving aliens at the port of entry.

(B) Eradication of foci already established. When the focus of infection has been established, with the prevention of the introduction of new cases its eradication can be hoped for. The statistics compiled by Dr. A. E. Davies, of New York, reveal the fact that prior to the classification of trachoma as a dangerous contagious disease by the United States Government in 1897, thus making mandatory the deportation of all aliens arriving who are so afflicted, the percentage of trachoma in one-half of a million cases of contagious diseases of the eye investigated by him was 4 per cent. Within three years after this restrictive measure was instituted an examination of nearly 100,000 cases revealed the presence of but a little over 2 per cent of cases of trachoma.

These figures are eloquent in what can be done by proper inspection, not only for the prevention of the introduction of trachoma into a community, but for its eradication. Nowhere is the trite saying, "Prevention is better than cure," more applicable than in the case of trachoma. It is highly important that countries and communities where the disease is not endemic, where no foci of infection have been started, where to exist it must be imported, should protect themselves from its ravages by proper legislation and inspection.

TRACHOMA.

By Passed Assist. Surg. J. W. Schereschewsky.

DEFINITION.

Trachoma is a disease of the conjunctiva, chronic in nature, prone to remissions and exacerbations, and characterized by an initial conjunctivitis, followed by the infiltration of the conjunctiva and subconjunctival tissues with lymphoid elements, which ultimately cause the destruction of the adjacent tissues, leaving behind a deposit of cicatricial tissue, which has a marked tendency to contraction.

ETIOLOGY.

HISTORICAL NOTE AND GEOGRAPHICAL DISTRIBUTION.

Trachoma is a disease of oriental origin. Our knowledge of it extends far into the past. References to it have been found in the writings of the ancient Greeks and Egyptians. Originally endemic in the Far East, and doubtless at first confined to rather restricted areas, it gradually worked its way westward, perhaps along the great caravan routes, until it became firmly domiciled along the southern littoral of the Mediterranean.

Owing to the fact that prior to the beginning of the last century references to the existence of trachoma in Europe are very indefinite, the return of Napoleon's soldiers from Egypt in 1802 has been blamed for its subsequent dissemination in the former country. Be that as it may, trachoma is now widespread throughout Europe and in some localities is the cause of 60 per cent of all cases of blindness.

It is particularly prevalent in Russia, Poland, certain parts of Austria-Hungary, as Galicia, and, in Germany, in East Prussia near the Austro-Hungarian and Russian frontier. Proceeding northward we find trachoma common among the denizens of the Baltic and North Sea littoral, especially in Finland and Holland.

In the south of Europe, Italy and, next to her, Greece are the countries more particularly cursed with this disorder. In Spain it is not uncommon, but is relatively rare in France. In England and Scotland the disease is infrequently met with, but the Irish are great sufferers from its ravages.

The following table gives the relative proportion that the number of cases of trachoma bear to that of other diseases of the eye encountered at the various representative clinics in different European countries:

	Per cent.		Per cent.
Russia	29	Turkey in Europe	18.3
Italy	27	Hungary	12
Greece	25	Holland	7
Portugal	25	France and Belgium	4
Bulgaria	20		

In considering the distribution and dissemination of trachoma we are at once impressed by the fact that, generally speaking, it is most prevalent in those nations which have an extensive seaboard, extends from the littoral to the interior, and, by its gradual extension from the coast into the rural districts, becomes domiciled in any country.

Trachoma is therefore essentially an imported disease, apparently does not originate de novo in any area, and its presence in such areas can nearly always be traced to cases which have originated from without.

In the United States trachoma has not as yet become general in its distribution. Owing to the great tide of immigration to this country we find it rather frequent along the Atlantic seaboard, especially in our large maritime cities, and practically always in persons either of foreign birth or foreign parentage.

Its presence is, of course, due to its importation previous to the enforcement of stringent measures against trachoma, and it is gratifying to note that, since the enforcement of such measures the number of cases of trachoma does not tend to increase. Owing to westward migratory movements, we also find trachoma prevalent to a certain degree among the inhabitants of the West. It has also been endemic for a number of years in certain restricted areas of southern Illinois and in the mountains of Kentucky and West Virginia.

So far as we know, the people from these areas are the only ones of strictly American parentage who may be said to suffer from trachoma; and the evidence is all in favor of the supposition that it did not originate in these areas, but was due to importation and, by reason of the comparative poverty and lack of medical facilities prevailing in these sections, was able to become firmly domiciled therein.

AGE.

Trachoma is a disease which may be contracted at any age, with the exception that very young children escape. This is doubtless accounted for by the fact that the adenoid elements of the conjunctiva are not present in the very young, nor do they develop until about the third year of life.

This explains the phenomenon, frequently observed, of large families in which all the older members are afflicted with trachoma, and in which the babe in arms and, perhaps the next oldest child, have not, as yet, contracted the disease, notwithstanding the fact that by reason of their tender years they must be particularly exposed to the infection by reason of parental and fraternal contacts.

INDIVIDUAL SUSCEPTIBILITY.

Individual susceptibility to the disease is undoubtedly a factor in its acquisition. It would seem that individuals with vulnerable lymphoid tissues are more prone to succumb to the infection. As an example, on the arrival of the North German Lloyd Steamship *Oldenburg* at Baltimore on February 6, 1907, 67 persons from the same compartment were found to be suffering from an inflammatory affection of the eye of the same general type, the origin of which was apparently due to the presence in their midst of four cases of trachoma in a state of acute exacerbation. Of these 67 affected aliens, 48 subsequently developed trachoma, while the remainder promptly recovered under simple remedial measures. Inasmuch as the inference is obvious that the infecting agent was the same for all, we can therefore predicate special resistance to the disease on the part of those who escaped.

FACTORS CONTRIBUTORY TO THE DISSEMINATION OF TRACHOMA.

The factors that facilitate the dissemination of trachoma are the conditions that prevail whenever human beings are closely crowded together, as on shipboard in tempestuous weather, in tenement houses in large cities, in schools, institutions, and factories. Add to this the poverty and unhygienic condition of city slums, the common use of the same water and towels for washing purposes, and, in the Orient, the fly, and it is obvious that such circumstances would serve to propagate freely any contagious disease.

MEDIUM OF CONTAGION.

No specific agent of the disease has as yet been isolated, though the medium of contagion is undoubtedly the secretion of the trachomatous eye. The transmission of the contagion may be by direct contact, or it may also adhere to the walls and floors of dwellings occupied by trachomatous subjects, assuming such places to be always in an overcrowded and filthy condition.

The discharge of the trachomatous eye has long been the object of patient bacteriological examination, and every organism capable of

exciting purulent inflammation has been found to be present in variable numbers, with the exception of any germ peculiar to the disease.

In 1882 Michal and Sattler announced that they had discovered a diplococcus in the trachoma discharge which they believed to have a causative relation to trachoma, but critical investigation seems to have unfavorably disposed of their claims. Nor has the investigation of the trachomatous tissue itself been more productive of results, as the bacterial flora so obtained has corresponded pretty closely to that of the discharge, which, as a rule, contains only the common pus cocci, such as the staphylococcus pyogenes aureus and albus and, occasionally, the staphylococcus citreus.

Yet the apparent specifity of trachoma and the constancy of the morbid changes induced by the disease certainly point to a microphytic origin, which will doubtless be discovered eventually.

MORBID ANATOMY.

In order to understand the nature of the changes which take place in the conjunctiva affected by trachoma a brief reference is expedient to the anatomical characteristics of this membrane.

It is a mucous membrane, lining the interior of the eyelid and extending over the anterior portion of the ocular globe. It presents for consideration a tarsal portion, a fornix, sinus or superior cul de sac, and an inferior cul de sac. The tarsal portion is closely and smoothly adherent to the tarsal plate, is of a faint yellow color, and exhibits but few blood vessels.

The sinus, retro-tarsal fold, or superior cul de sac is but loosely attached to the underlying tissues, is of a reddish color, and is richly supplied with blood vessels.

The ocular conjunctiva presents a white, glistening appearance, and lies smoothly over the globe, although loosely attached to it, so that a fold is readily pinched up with forceps. At the corneal margin it becomes intimately blended with the superficial epithelial cells of the cornea.

The different portions of the conjunctiva vary in structure. The tarsal portion, though apparently smooth, has a somewhat velvety surface marked with fine grooves and pits distributed in an irregular reticulation, the so-called papillæ. Beneath its epithelial surface is a layer rich in elastic fibers, between whose interstices lymphoid cells are diffusely distributed. Scanty at the tarsal border they become more numerous as we proceed toward the retro-tarsal fold, in which situation they are gathered into numerous congeries, thus forming distinct lymph follicles. We also find these follicles abundant in the inferior cul de sac.

The amount of this lymphoid tissue varies in different individuals, and it is absent in the first years of life.

In addition to the lymphoid elements of the conjunctiva it has also numerous mucous follicles distributed over the tarsal conjunctiva, and especially in the superior cul de sac.

It is the layer of adenoid tissue that is the site of invasion in trachoma, and it is the pathological changes taking place in these lypmhoid elements that constitute the phenomena of the disease.

Opinion is divided as to whether the changes observed in the trachomatous conjunctiva are the result of inflammation or are a new growth of a grannulomatous nature, and long and acrimonious have been the discussions over this question. The most likely supposition, in the light of our present knowledge, is to regard trachoma as a chronic inflammation which, affecting at the outset the mucoid corpuscles of the conjunctiva, extends, by contiguity, into its deeper layers and finally involves this subconjunctival adenoid tissue. As a result of this inflammation, there is a development of new lymphoid cells and of an inflammatory exudate. These lymphoid cells, exuded by inflammatory action, are collected by the pressure of surrounding inflammatory products into follicular masses of a low order of vitality, which, having once attained this condition, become of the nature of foreign bodies, which the organism consequently sets about either extruding or absorbing.

We therefore find the trachoma follicle presenting the appearance of a spheroidal mass of lymphoid cells, many of which are in a state of hyaline degeneration, surrounded by a capsule of inflammatory connective tissue, well supplied with newly formed blood vessels. From these vascular twigs tenuous loops project into the interior of the follicle, and a stroma of delicate connective tissue cells fills the interstices between the lymph cells. This stroma is more evident at the periphery of the follicle than in the central portion, where the lymph cells are closely massed together and, in many cases, have undergone degeneration.

The conjunctival epithelium overlies the trachoma follicle, which, by reason of the presence of the inflammatory products behind, is pressed outward more and more and, as a consequence, tends to become progressively more prominent. This ever increasing pressure, as well as, perhaps, a certain toxicity inherent in the follicle itself, causes, at first, hyaloid degeneration and then subsequent destruction of the conjunctival epithelium covering it, so that eventually the follicle protrudes through the conjunctiva, its contents are extruded, and the remains of its capsule become the seat of deposit of cicatricial tissue, which is also probably deposited to a greater or less extent in those areas once filled with inflammatory exudate.

SYMPTOMS AND COURSE.

It is difficult clinically to classify trachoma. Inasmuch as the appearances observed depend upon different stages in the same pathological process, its phenomena will vary greatly, according to the degree of development of the disease and the susceptibility of the affected individual.

Much confusion has arisen by reason of the nomenclature applied to the clinical pictures observed in trachoma in its various stages and the terms "acute inflammatory trachoma," "mixed trachoma," "chronic trachoma," and the like only serve to obscure instead of to clarify our conception of this disorder.

The writer believes it preferable to regard trachoma as a series of changes taking place in the palpebral tissues as the result of long-continued inflammation and the retrogression thereof and, for the purposes of description, has, in this memorandum, divided the trachomatous process into the following stages:

(a) Stage of invasion.
(b) Stage of extrusion of follicular contents.
(c) Stage of cicatrization.

STAGE OF INVASION.

The initial symptoms of trachoma are those of a conjunctivitis. By many it is supposed that the disease may be insidious in its onset and that any inflammatory symptoms observed are due to previously developed trachoma follicles. This supposition seems to be founded upon conjecture alone, as the opportunities for the observation of the disease, in its incipiency, in eye clinics at least, are very rare, as patients do not, as a rule, apply for treatment until the disease is well advanced.

On the contrary, the facilities afforded for the observation of the earliest beginnings of trachoma in the inspection of arriving aliens surpass greatly those in other fields of investigation. The result of a large number of observations incline the writer to the belief that the onset of trachoma is, in every instance, characterized by an initial conjunctivitis, differing somewhat, however, from the ordinary catarrhal or mucopurulent form, and usually of a grade proportionate to the virulence of the infection.

In fact the histology of trachoma would seem to support this hypothesis, for, in so far as we can judge, the extension of the inflammation is from without inward, and there is no essential difference in this pathological process from that of long continued inflammation in any other part of the body, with the exception that its phenomena are more accessible to observation.

The subjective symptoms of the initial conjunctivitis are similar at first to those of the ordinary form. There is the usual discomfort and difficulty or inability in using the eyes, the sensation of itching or burning or of a foreign body between the lids. The secretion may be profuse, and is usually watery or somewhat mucopurulent. As a rule the secretion is somewhat less than would be warranted by a similar degree of inflammation due to some other cause. The eyelashes are matted together by the secretion, and on attempting to open the eyes after sleep the lids are found to adhere. The eyelids appear slightly swollen and somewhat thickened. Owing to increased lachrymation the eyeball presents a glistening appearance. Some enlargement of the preauricular and possibly the submaxillary lymph glands can usually be made out.

The ocular conjunctiva is but moderately congested. On casual inspection this may not appear to be the case, but upon close examination it will be noted that the congested appearance is due in no slight degree to the engorgement of the vessels of the sclerotic, especially in the region of the vertical equator of the globe and the circumcorneal zone. This congestion of the sclera, shining through the interstices of the conjunctival vessels, gives to the eyeball a hue of diffuse rosy pink.

On everting the lids we were impressed at once with the difference in degree of the congestion of ocular and palpebral conjunctiva, respectively. The latter is deeply and darkly red, especially in the regions of the superior and inferior cul-de-sacs where it presents an appearance of succulence, redundancy, and œdema and is thrown into longitudinal folds or plications.

This is the reverse of the conditions which usually obtain in simple forms of conjunctivitis, in which, as a rule, the ocular conjunctiva is the more deeply congested, and, if the palpebral conjunctiva be involved, the congestion is usually limited to the tarsal portion and does not so markedly involve the retrotarsal fold. Moreover, if the inflammation in simple forms of conjunctivitis be sufficiently severe to cause œdema, this usually affects the ocular conjunctiva, causing chemosis, while further œdema caused by the inflammation affects the *subcutaneous* tissues of the lids rather than the tissues underlying the conjunctiva of the superior and inferior cul-de-sacs.

The conjunctival papillæ are much enlarged and swollen. That inflammatory diapedesis is already commencing is shown by the dilatation of the conjunctival vessels and the merging of their outlines, usually so distinct, into the general congestion. This infiltration

is further demonstrated by the thickening and commencing stiffness of the lids.

As the invasion progresses we observe an increasing succulence of the palpebral conjunctiva. This membrane, as well as the tissues of the eyelid as a whole, is increased in thickness. The engorgement and prominence of the conjunctival follicles, together with the exudation of inflammatory products, give to the palpebral surface a granular appearance, later to be intensified by the approach of the so-called trachoma follicles to the surface.

STAGE OF FOLLICULAR EXTRUSION.

As the disease progresses the degree of inflammatory reaction at first present usually subsides to a great extent, although it is subject to exacerbations and remissions. If the attack be virulent, it may hardly be said to subside at all, and, by its presence, increases remarkably the amount of inflammatory exudate, the proliferation of trachoma follicles, and, in general, the ravages of the disease.

The presence of the accompanying inflammation may at first obscure to a great extent the detection of the trachoma bodies, but as it subsides they come more prominently into view and can be discerned as small, rounded elevations, 1 or 2 mm. in diameter, apparently embedded in the conjunctiva and rising above its general level.

Their color is influenced by the degree of congestion of the eyelid. If the initial inflammation has, for the most part, subsided, and the trachomatous process is momentarily quiescent, their color is grayish or grayish pink. If, however, inflammation be still active, they may be deeply red. They are surrounded by the enlarged mucous follicles of the conjunctiva, and it is to the coarsly granular appearance of the trachoma bodies and the enlarged conjunctival follicles that the name "granular conjunctivitis" is due.

The trachoma follicles show a tendency to collect, at first in isolated groups, and then, partially coalescing, to form masses which have been designated as "frog spawn" or sago grain granulations. (Fig. VI.)

Their seat of election appears to be along the border of the retrotarsal fold and in the superior cul de sac, from which extensions are thrown out upon the tarsal surface. They are also abundant, at least in the earlier part of the disease, in the inferior cul de sac. It is well to state, at this point, that the presence of the trachoma granule is to be made out in the inferior cul de sac some time before the involvement of the upper lid is manifest, as infiltration usually commences in this situation. They also disappear from this region often long before redintegrating changes have taken place in the upper lid.

The trachomatous process is also said by some occasionally to extend to the ocular conjunctiva, but the writer has not been able ever to confirm this by personal observation.

The granulations may be limited to a small portion of the palpebral conjunctiva or they may involve its entire surface. It is not probable that in cases of ordinary intensity the subconjunctival adenoid tissue is involved, *ab initio*, in its entirety, and the subsequent exacerbations signalize, as a rule, a further extension of the disease.

With the full development of the trachoma body the next step in the progress of the disease would seem to be an effort by nature toward a cure. The trachomatous follicles themselves, consisting as they apparently do of effete and obsolescent lymphoid corpuscles, appear to act in the nature of foreign bodies, as do tubercles, and similar granulomata in other tissues, and it is the efforts of nature at their extrusion which bring about the morbid changes observed as a result of this disease.

As the disease progresses the subsidence of the acute inflammation and also the *vis a tergo* of the inflammatory exudate causes the trachoma follicles to approach the conjunctival surface. Their epithelial covering becomes devitalized, attenuated, and finally destroyed, and the follicular contents are extruded, leaving behind the vascular remnant of their capsule, which ultimately becomes the seat of cicatricial deposit.

The symptoms present at this stage vary greatly. They depend upon the extent of the areas of conjunctiva involved, the degree of thickening of the lids, and the presence or absence of corneal complications. In many cases the subjective symptoms, after the subsidence of primary inflammation, are trivial and the disorder is manifest only upon eversion of the lids. In other cases the symptoms are severe, photophobia, lachrymation, severe itching or burning being continually complained of and making the life of the sufferer a burden.

It is in this and the subsequent stages that exacerbations and remissions are marked, exposure to dust, smoke, salty air, unhygienic conditions, and a vitiated atmosphere bringing on a fresh accession of inflammatory symptoms with a subsequent aggravation of the local manifestations.

On examination the lids will be found to be thicker and stiffer than previously. Partial ptosis is frequently present. This is largely mechanical, and is due to the inability of the levator palpebrae completely to retract the thickened eyelid beneath the border of the orbit. This brings about the narrowing of the palpebral fissure, commonly spoken of as one of the external manifestations of trachoma. On eversion of the lids, a process which may be difficult on account of their thickened condition, the presence and number of the trachoma

follicles at once strikes the attention. The sudden eversion of the lid may be attended by the rupture of several follicles and the extrusion of their gelatinous contents may be observed, leaving behind a bleeding point, which marks the position of the vascular follicular remnants. The mass of granulations obscures the outlines of the conjuntival vessels. Thickest in the region of the retrotarsal folds, it sends out extensions upon the tarsal surface, or the granulations may have so extended and coalesced that the entire tarsal plane presents nothing but a thick brawny mass of lymphoid induration, whose individual granules are so closely packed that their granular outline is so modified as to present a tesselated appearance.

STAGE OF CICATRIZATION.

This and the previous stage merge into each other and there is no definite dividing line between them. The commencement of this stage is inferred by the appearance of the cicatricial deposit which marks nature's steps in her cure of this disorder. Owing to the more or less longitudinal disposition of the trachoma follicles, the cicatricial deposit takes place in bands running lengthwise of the lids. The mass of scar tissue formed is directly proportionate to the amount of trachomatous deposit previously present and to the degree of inflammatory infiltration. This deposit may be represented merely by a faint white line along the border of the retrotarsal fold, or the whole conjunctiva may become a sere, yellowish, wrinkled, roughened cuticular surface, with posterior symblepharon and obliteration of the superior cul de sac.

This process of cicatrization takes place *pari passu* with that of follicular extrusion. Hence, we find areas perfectly cicatrized over which the conjunctiva is smooth, surrounding islets in which the process of follicular ulceration and extrusion is active and others in which trachoma follicles have not as yet been developed.

The ultimate effect of the development of scar tissue is to accomplish, by its subsequent contraction, the inversion of the palpebral border, thus producing entropion, and also by reason of the roughness of the interior of the lids, to cause corneal complications or perpetuate them if already present.

COMPLICATIONS AND SEQUELÆ OF TRACHOMA.

Owing probably to mixed infection, the onset of the disease may be so severe as to compromise the vision from the outset. As a result of such acute infection early and profound ulceration of the cornea may ensue, with purulent infiltration of the cornea, hypopyon, perforation, and evacuation of the contents of the eyeball.

The cornea, as a rule, almost always becomes implicated at some stage of the disease in untreated trachoma. This corneal involvement takes the form either of superficial ulceration, pannus crassus, pannus tenuis, or keratitis.

It would seem that devitalization or destruction of the epithelium of the palpebral conjunctiva, and not the intrinsic roughness of the lids, is the prime cause of early complications. The presence of such early complications predicate the extension of the disease to the tarsal plate; hence we find them absent, as a rule, when the disease is limited to the cul de sac. The absence of this condition of epithelial devitalization or destruction which originates corneal complications also explains the existence of relatively profuse granule formation with but little corneal involvement, and conversely severe corneal involvement with apparently trivial palpebral lesions.

The type of corneal involvement in the earlier stages of the disease usually consists of superficial and localized ulcerations, which are attended with intense pain, lachrymation, and photophobia. The later corneal complications consist of pannus and keratitis. The pannus is of two forms, the so-called panus crassus, and pannus tenuis. Pannus crassus consists of the overgrowth of the cornea with a thick and fleshy mass of newly formed vessels and tissues, so dense at times as to hide the iris from view. This form of pannus is usually developed at a relatively early stage of the disease, commencing when the tarsal invasion of the eyelid is complete. It is to be regarded as a desperate effort on the part of the cornea to interpose a shield between it and the layers of effete conjunctival epithelium perforated by trachoma follicles that menace its integrity.

The form of pannus caused by the rubbing of the roughened interior of the lids or the inturned eyelashes in the later stages of the disease is apt to be less vascular in its nature, and takes the form of a haziness or cloudiness of the corneal surface, across which the outline of a few slender vessels descending from the corneal limbus can usually be made out.

The effects of cicatricial contraction in the lids resulting from trachoma are also important elements in the causation of corneal complications. The occurrence of entropion in this disease has already been adverted to and constitutes one of the most serious results of trachoma.

The destruction of the conjunctiva and the adjacent parts of the tarsus causes incurvature of the tarsal border, which, when present in any considerable degree, brings the cilia into contact with the eyeball. The constant irritation of their friction perpetuates a keratitis, which may be followed by softening and ulceration of the corneal tissues and may result in total corneal opacity, staphyloma, or perforation and panophthalmitis.

The occurrence of iritis is not uncommon in severe cases of trachoma. It may be the result of severe circumcorneal congestion, or may complicate ulceration of the cornea, or keratitis. When it occurs it is always the result of the initial inflammation or an intercurrent exacerbation.

ULTIMATE EFFECTS OF TRACHOMA UPON THE VISION.

Without dwelling upon the truly desperate conditions that may result from the ravages of trachoma, it is astonishing to what degree even apparently insignificant alterations in the corneal tissues, the result of this disease, may reduce the sight. Even slight haziness of the cornea, which to the naked eye is hardly apparent, often sadly obscures the vision, so that a visual reduction to one-tenth the normal may be a fortunate result. Moreover, the pressure of the thickened lids and the macerating influence of the trachomatous secretion may so soften the corneal tissues and alter the corneal curvature that high degrees of irregular astigmatism which are not susceptible of correction by glasses are often encountered, which greatly diminish the acuity of the sight.

Such then is the general course of the disease. It must not be inferred that the progress toward cicatrization is always uniform. On the contrary the disease is peculiarly prone to exacerbations and remissions and a sudden ingravescence of the disorder, by extending the area of invasion, may at any time completely nullify the effects of careful previous treatment.

DIAGNOSIS.

The diagnosis of trachoma will be discussed, especially with reference to the detection of the disease in immigrants. It goes without saying that the position of medical officers engaged in the examination of aliens differs materially, with reference to trachoma, from that of medical practitioners in general. In the case of the latter a mistake in the diagnosis of trachoma is fraught with no injustice, and the speedy cure that follows treatment in such cases redounds only to the credit of the physician. In the medical examination of immigrants quite the contrary is the case. Failure to recognize the disease leads to the admission of a contagious disorder, dangerous to vision, while the miscertification of other diseases of the eye as trachoma accomplishes the deportation of the alien concerned, thus inflicting consequences not only unjust in the highest degree, but even tragic in their results. It is therefore axiomatic, for the purposes of executing the immigration laws, that the correct diagnosis of trachoma is of the highest importance, and never lightly to be made, and that, moreover, some uniformity of opinion is highly

desirable so that similar eye conditions will receive identical disposition at the hands of the medical examiners at the various immigrant stations.

These remarks will not apply to typical cases of trachoma, the appearance of which is characteristic and always readily to be recognized. They refer rather to those conditions on the border line which require such working basis for disposition as will, in the long run, be productive of the best and most uniform results.

As already stated, cases of well-developed trachoma are fortunately easy to diagnose. The thickened and infiltrated condition of the lids, the granular condition of the conjunctiva, the presence of ptosis, all form a picture, once seen not to be forgotten. The mild cases, however, which, as far as we know, may be just as liable to exacerbation, and consequent spread of the disease as the severe, are the ones which "give us pause." In the acute stage they are likely to be confused by the inexperienced with cases of catarrhal, mucopurulent, or epidemic conjunctivitis (pink-eye); in the quiescent stage with follicular conjunctivitis.

As aids in the diagnosis of trachoma in the initial stage, the following points, which distinguish it from ordinary inflammations of the eye, may be enumerated:

(a) From the first the tendency of trachoma to cause infiltration of the sinus and inferior cul de sac, is manifest. This is evidenced by the deep congestion of the conjunctiva in this situation, its apparent redundancy, and succulent appearance.

(Note.—It may be remarked that this apparent redundancy and congestion is, as a rule, manifest in the inferior before it is apparent in the superior cul de sac.)

(b) The only moderate degree of congestion of the ocular conjunctiva as compared to that of the palpebral portion.

(c) The practically constant occurrence at an early stage of a degree of congestion of the vessels of the sclerotic, especially at the vertical equator of the eyeball, and the circumcorneal zone, which is inconsistent with the general local symptoms.

(d) The character of the conjunctival secretion, which is watery, or at most, mucopurulent.

(e.) The resistance of the inflammation to simple remedial measures.

These points assist us, at least, in forming an opinion as to the ultimate outcome of any inflammation of the eye which may present itself among arriving aliens. Practically, however, any conjunctivitis must be regarded as suspicious, especially in the presence of cases of active trachoma among arriving aliens, and call for careful examination. If there is any doubt as to its simplicity, the affected individual should be held for observation for any reasonable time.

It may, however, be stated that any inflammatory infection of the eye, which resists simple remedies for two or three weeks, is accompanied by infiltration of the conjunctival tissues, and shows no tendency to improve in that time, is trachoma and should be so certified.

It is mainly in the absence of opportunities for holding immigrants for observation that mistakes in the diagnosis of trachoma in its initial stage are apt to occur, and under such circumstances the determination of the presence or absence of the characteristics of trachomatous inflammation in the early stages previously alluded to will be serviceable in arriving at a diagnosis.

It should not be forgotten that any moderately severe attack of simple conjunctivitis, which has lasted several days, causes a certain degree of prominence of the follicles of the conjunctiva in the region of the tarsal plate. The true index of trachomatous inflammation, however, is absent; namely, infiltration of the cul de sacs.

Follicular conjunctivitis in some respects presents a similarity to trachoma in the quiescent stage. In fact, some authors go so far as to designate it as "simple follicular trachoma." This designation the writer regards as most unfortunate, as he believes that it has nothing in common with trachoma, beyond perhaps indicating a susceptibility to this disease.

Follicular conjunctivitis consists of a hypertrophy of the normal follicles of the conjunctiva, which affects children for the most part, and is characterized by the development in the palpebral conjunctiva of a large number of hemispherical projections of a grayish or pearly color, resembling a hemp seed in general contour. In distribution they correspond to that of the normal conjunctival follicles. Their presence does not arouse active proliferation of the conjunctival blood vessels, so that the normal vascular supply of the conjunctiva is unaltered by their presence. Moreover, no infiltration of the palpebral tissues takes place, nor is the structure of the conjunctiva between the enlarged follicles altered in any way. The symptoms caused by follicular conjunctivitis are relatively slight, and the disorder may be regarded merely as the expression of unusual lymphoid activity on the part of the individual concerned. We are therefore justified in considering that the occurrence of follicular conjunctivitis may be regarded as the index of tissue rich in lymphoid elements, and for this reason vulnerable to trachomatous infection. This would be a legitimate cause for the removal of this condition by appropriate treatment; and, at all events, cases which give rise to the slightest doubt in the diagnosis should be held for observation and treatment in the hospital, where a simple expression of the follicular contents will usually succeed in removing the disease.

Vernal catarrh and Parinaud's conjunctivitis are also inflammatory conditions of the eye which, though rare, have been confused

with trachoma. The clinical picture in vernal catarrh may superficially resemble rather closely the picture of trachoma in an acutely inflamed condition. It is, however, distinguished from trachoma by the inflammation and swelling of the ocular conjunctiva in the vicinity of the corneal limbus; by the structure of the papillary elevations, which are true fibromata, and the history of a repeated occurrence of the disease at stated periods of the year.

Parinaud's conjunctivitis also simulates a severe attack of trachoma. Its distinguishing features are that it is usually unilateral, is accompanied by fever and general constitutional disturbance, swelling of the subcutaneous tissues of the lids is present, and the granules formed are larger. There is a tendency to early corneal ulceration, as well as to the formation of discrete ulcers of the palpebral conjunctiva, and there is notable enlargement of the preauricular and submaxillary lymph glands. The preauricular gland almost invariably suppurates in the course of the disease.

Another phase which complicates the diagnosis of trachoma for the purposes of the execution of the immigration laws is the satisfactory determination of that stage of this disease when it may be regarded as cured and incapable of further dissemination. Not a few immigrants are encountered who present the evidences of former ravages of trachoma, and it is highly important to ascertain whether the individual in question is at present thoroughly cured or whether he is still liable to exacerbations of the original infection.

Immigrants who present on examination the scars resulting from trachoma, but in whom the conjunctiva is smooth and unmarred by localized areas of granulation or plaques of lymphoid infiltration may be regarded as cured of the disease, and consequently may be passed, although the presence of corneal opacities, keratitis, or trichiasis will call for certification of the local condition. Those cases which present cicatrices of trachoma, but which in addition still have areas of granulations unconverted into cicatricial tissue, must, although the eye be apparently quiescent and free from secretion, be regarded as potentially capable of transmitting the disease and be disposed of accordingly.

METHOD OF EXAMINATION FOR TRACHOMA.

There can be but one method to assure the absolute detection of trachoma among arriving aliens; that is, the eversion and examination of every eyelid.

After a little practice the eversion of the eyelid is easily accomplished by the thumb and forefinger of either hand. Those who have not had the opportunity for the acquisition of dexterity in performing this little maneuver may easily accomplish the eversion by means of a hairpin, glove buttoner, or stick of wood with rounded

ends. Every individual whose eyelids present any unusual appearance, as of enlarged conjunctival papillæ, thickened eyelids, eyelids difficult of eversion, conjunctival congestion, muco-purulent secretion, pannus, keratitis, and the like, should be placed to one side to undergo further critical inspection at the close of the primary examination.

Such inspection should be painstaking and thorough and should include observation of the following points:

(1) State of the ocular conjunctiva and of the sclerotic, whether congested or not, etc.

(2) Presence or absence of secretion.

(3) Appearance of the inferior cul-de-sac, whether redundant, congested, etc.

(4) Appearance of the cornea, whether involved or not.

(5) Eversion of the upper eyelid and exposure of the retrotarsal fold.

(6) State of tarsal conjunctiva, presence or absence of congestion, or of enlarged papillæ or granulations.

(7) State of the superior cul-de-sac, whether redundant or not, its state of vascularity, condition of infiltration, presence or absence of granulations, etc.

All cases which are not obviously cases of simple conjunctivitis should be held in some suitable place for further observation and treatment, and the eyes of such detained aliens examined daily if practicable. Under such circumstances cases of doubtful conjunctivitis will rapidly clear up, while cases of trachoma will remain in statu quo or become worse, and thus are readily recognized.

One should not forget the possibility of the occurrence of a simple conjunctivitis in the eye of an individual who has previously suffered from trachoma and bears the scars thereof. Such an eye presents a minatory appearance which would incline the examiner to certify it as trachoma on the spot. In such cases, however, unless the presence of active granulations or plaques of lymphoid infiltration show the trachoma to be indubitably active, the alien should be detained under observation until the inflammatory phenomena have subsided or until at least all doubt is at rest as to whether the case in question is merely simple conjunctivitis in a previously trachomatous eye or is the acute exacerbation of chronic trachoma.

PROGNOSIS.

There is no question that trachoma is a serious disease and not lightly to be regarded. The menace to the vision in any untreated case of trachoma is very real, even in cases initially mild, as subsequent exacerbations may induce a train of destructive corneal lesions. In the absence of appropriate treatment haziness of the cornea is a

frequent sequel even in the mildest cases, and it has already been shown to what an extent an even apparently unimportant degree of obscuration of corneal lucidity will reduce useful vision. The change in corneal curvature which takes place under the softening and macerating effect of the disease and the increased pressure of the lids has also been adverted to, and also the difficulty or impossibility of the correction by glasses of the irregular astigmatism thereby induced.

Appropriate treatment is in most cases able to modify the course of trachoma. In mild attacks early and careful therapy may effect a practical restitutio ad integrum. In severer forms of the disease, provided the degree of infiltration be not too great and confined to the cul-de-sacs, the same result may be achieved after a longer struggle. It is the cases of long standing, with pannus and brawny induration of the lids, which resist our therapeutic measures. In such cases a long course of treatment, extending over months, seems to effect but trivial results in modifying the course of the affection. In general, it may be said that the longer the duration of the disease the harder it is to cure and the less likelihood there is of such cure being effected without leaving some permanent visual defect behind.

TREATMENT.

To describe in full all the various remedial measures which have been advocated for the cure of trachoma, and the special conditions in which they may be essayed, would be beyond the province of this memorandum. The basic principle of treatment is to facilitate nature's attempts at a cure, and above all to prevent or restrict as far as possible corneal complications.

To this end our methods should not be too harsh in the initial stage of the disease. At this time the paramount indication is to reduce the inflammatory symptoms as soon as possible in order to restrict the production of inflammatory infiltrate. All more active measures must be postponed until the eye is in practically a quiescent condition.

The patient should, therefore, be placed in a darkened room; cold applications are to be made to the eyes for two hours at a time, with an interval of one hour. Three times a day a 20 per cent solution of argyrol should be instilled into the eyes and any secretion present be removed by washing the eye with a 4 per cent solution of boric acid or deci-normal salt solution.

After the subsidence of the initial inflammation a critical inspection of the interior of the eyelid will decide the remedial measures to follow. If the degree of infiltration be not very great and the trachoma granules are soft and prominent, expression will probably give the best results. This is accomplished by thoroughly cocainizing the parts; the eyelids are everted, and by means of Knapp's roller

forceps or Noyes' forceps the contents of the trachoma follicles are expressed. The degree of force applied should be just sufficient to rupture the follicles and cause moderate hemorrhage. Some reaction will usually follow this operation and is to be combated with cold applications and mild antiseptic washes. If the degree of lymphoid infiltration be great it may be reduced, as a measure preliminary to expression, by longitudinal scarification of the infiltrated areas, repeated at intervals of several days.

If this is successful in reducing the infiltration we may then proceed with expression to remove the follicular contents. Cases, however, in which the infiltration is persistent, thickening is great, and in which the trachoma granules are hard and deeply embedded are not suited to expression. Treatment in such cases must be directed toward the removal of the effete epithelium, which overlies trachoma follicles, and permit their approach to the surface. To accomplish this grattage is very effective. The eyelids, previously cocainized, are everted and scrubbed hard with a toothbrush which is dipped in a 1 to 500 solution of bichloride of mercury. The resulting reaction is combated as usual with cold applications and mild eyewashes.

Granulating areas which remain after these measures are touched daily or every other day with a crystal of copper sulphate and instillations three times a day of the 20 per cent solution of argyrol are continued.

Corneal complications are treated as they arise. Ulceration requires the dilatation of the pupil with atropine and hot applications to the eye. If, in spite of treatment, the ulcer shows a tendency to spread it should be cauterized with the hot iron. The electro-cautery is the best instrument for this purpose, but in its absence good results can be obtained with a silver probe or even a hairpin heated in an alcohol flame. The development of pannus crassus must be regarded as a protective process on the part of the cornea and is remarkably improved by the retrocession of the disease in the lids. The pannus due to the trichiasis resulting from entropion consequent on trachoma is also much improved by operations which remove the entropion.

No matter what local remedial measures are applied, anything which improves the general condition of the patient assists materially in modifying the course of the disease. Hence hygienic surroundings, plenty of fresh air, and a nutritious diet will assist as much as anything else in our treatment of trachoma.

In general it may be said that the mildest case will require one to three months' treatment to effect a cure. While the time required for cases of moderate severity can not be definitely predicted, it may be all the way from six months to years.

Under our existing laws, however, medical officers engaged in the examination of aliens have but little to do with the curative treat-

ment of trachoma. They are of necessity restricted to the more or less simple remedial measures used to determine the nature of the disease under observation. Of course complications present at the time of primary inspection which menace the integrity of the eyesight or by their severity render the alien concerned unable to travel must receive such treatment as is indicated, but, generally speaking, the application of therapeutic measures is limited to those which are serviceable in the simpler forms of inflammation of the eye.

The main object of such treatment is to cure a simple conjunctivitis or to clear up any intercurrent conjunctivitis in old cases of trachoma so as to render the nature of the affection, if trachoma, evident as soon as possible.

Generally speaking such remedial measures will be confined to cold applications when there is much inflammation present, removal of secretion as soon as formed by mild antiseptic lotions, and the instillation of 20 per cent solution of argyrol three times a day. Under such conditions any simple form of eye infection rapidly clears up, while the most that will be effected in the case of trachoma will be the reduction of the eye to a more or less quiescent condition. In children who present what is apparently a simple follicular conjunctivitis, treatment by expression should be employed, as in such cases the reaction is usually trivial. One application of the forceps is curative in most instances and a condition which certainly must be regarded as predisposing to trachoma is removed.

PROPHYLAXIS.

It is easier to prevent trachoma than to cure it. When we consider that the presence of the disease in any area practically implies its previous importation and that in some sections of Europe 60 per cent of all cases of blindness are due to this disease, the position the Government has taken to prevent the further importation of a disorder dangerous to sight needs no defense.

The best national prophylaxis is therefore the exclusion of aliens suffering from trachoma. In regard to the trachoma that is already in our midst that is a matter for the care of State and municipal health authorities. The writer believes that the condition of the eyes of school children, especially of those of the poorer classes and in the higher grades, can be taken as a fair index of the general prevalence of trachoma in the locality under consideration. The eyelids, therefore, of all school children should be systematically inspected and those who present evidences of trachoma should be excluded from school attendance. By following up such cases to their homes the presence or absence of trachoma in their immediate family may then be determined. Moreover, physicians should be required to

report cases of trachoma which they observe among their patients. In respect to the prophylaxis of trachoma, when it is found among members of institutions, such as orphan asylums, almshouses, and the like, persons suffering from the disease should be isolated and they should not be allowed to use wash basins, towels, bed clothing, or garments which are accessible to other members of the institution.

In wards which are set apart for the treatment of cases of trachoma the following precautions should be observed, not only to prevent the reinfection of cases which are making progress toward recovery, but also for the protection of the nurses and physicians who come into contact with such patients. As far as practicable all patients who present acute inflammatory symptoms should be grouped together in one ward and have attendants who care for them exclusively. Each patient should be provided with a supply of pieces of sterilized gauze for use in wiping the face and eyes; such pieces should be used but once for that purpose and should afterwards be destroyed. If practicable, each patient should be supplied with his own hand basin and towels for washing purposes, and if this is not expedient, only washing in running water should be allowed. Nurses, when they are applying instillations or irrigations to the patients' eyes, should protect their own by suitable goggles, and they should be particular to disinfect their hands in passing from one case to another and also at the end of the application of treatment. Similar precautions should be observed by physicians in charge of such wards.

The prophylaxis of trachoma on shipboard includes the frequent examination of the passengers' eyes, and the prompt segregation of any passenger who exhibits any form of inflammatory affection of the eye.

ECONOMIC CONSIDERATIONS.

It is manifest from the foregoing that we must concede to trachoma a high place among the factors that go to decrease materially not only the economic efficiency of the individual sufferer, but that of the race or people, as a whole, among whom it is prevalent. In addition to the well-nigh constant bodily discomfort of the individual sufferer, the resulting visual impairment can not fail greatly to reduce his efficiency and, consequently, his value to society at large. The gradual increase in the prosperity of any community depends almost exclusively upon the ability of the individual members of such community to raise their own standard of living. Such improvement in their material condition is, in its turn, dependent upon the productive capacity of the individual unit. One can hardly, therefore, urge that a person afflicted with a chronic disorder such as trachoma, which, in addition to the depression induced by the constant discomfort and bodily suffering of the disease, tends to impair one of the

most essential senses of the body, can be on a par in productive capacity with the healthy individual, apart from any danger to which he may expose the community at large by his ability to disseminate the disease.

As a consequence, we find that as the earning capacity of the individual sufferer from trachoma decreases by the resulting impairment of his vision he is obliged at once to satisfy himself with a progressively lower standard of existence, thereby not only exposing himself, but those who are dependent upon his efforts to those conditions of increasing poverty, filth, and unhygienic surroundings which are known especially to foster the disease and facilitate its distribution. In this manner the vicious circle is completed. Nor do the inimical effects of trachoma upon society at large end with the downfall of the individual sufferer. It would be fortunate if they did. We must not forget that the children of the present are to constitute the active producing members of the community of the future and that the general status of the future community is dependent upon the degree of intelligence which we are able by education to confer upon our children. School children attacked by this disease must be excluded from school attendance at a time when their faculties can but illy afford to lose this training if they are to develop their highest qualifications as useful social units. Owing to the chronicity of the disease they are kept from school for long periods of time, and in addition to this their subsequent recovery may leave them with such visual defects as to forever militate against their attaining their predestined mental standard.

O

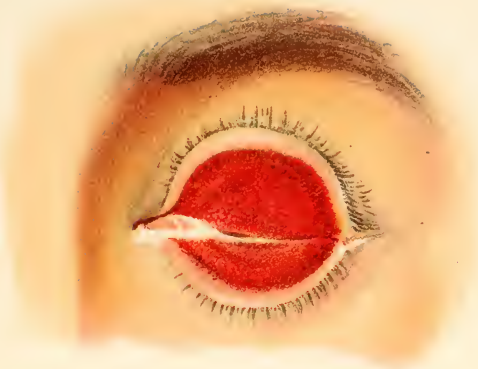

FIG. 1.—ACUTE TRACHOMA WELL DEVELOPED WITH GENERAL DISTRIBUTION OF THE GRANULATIONS IN BOTH THE SUPERIOR AND INFERIOR CUL DE SACS.

FIG. 2.—TRACHOMA—BEGINNING CICATRIZATION

J. H. Wilder del

FIG. 3.—TRACHOMA—CICATRIZATION WELL MARKED.

FIG. 4.—TRACHOMA—SHOWING GRANULATION TISSUE FORMATION.

FIG 5.—TRACHOMA—CICATRIZATION ALMOST COMPLETE.

FIG. 6.—TRACHOMA—CURED, MUCOUS MEMBRANE REPLACED BY SEAR TISSUE

L. H. Wilder, del

PREUNER & KESSLER CO. PHILAD^A